

Ivermectin treatment of lice infestations in two elephant species—

William B. Karesh, DVM, and Phillip T. Robinson, MS, DVM, Jennings Center For Zoological Medicine, Zoological Society of San Diego, PO Box 551, San Diego, CA 92112

INFESTATION by the elephant louse, *Haematomyzus elephantis* was diagnosed in 5 Asian elephants (*Elaphas maximus*) and in 4 African elephants (*Loxodonta africana*) maintained at the San Diego Zoo. The elephants had lice on the posterior surface of the ear pinna and on the head and neck areas caudal to the ears. Severely affected elephants had lice extending from the previously described areas to other skin surfaces protected from exposure to direct sunlight. The reddish brown, approximately 1 to 2 mm long lice were attached firmly to the skin and were difficult to remove manually. Eggs were firmly adherent to the base of hair shafts on all elephants.

The elephants were treated orally with an injectable ivermectin preparation.¹ Dosages ranged from 0.059 mg/kg of body weight to 0.087 mg/kg. The elephants ranged in age from 2 to 46 years and in estimated weight from 680 to 3,400 kg. Within 48 to 72 hours after treatment, the lice became easier to remove manually. Seven days after treatment, lice were not found on any of the elephants. Five to 6 weeks after the first treatment, ivermectin was given again to each elephant using the same route of administration and the same dose. At the time of the second treatment, a few lice were present, but eggs were not found on the elephants. Subsequent reinfestation has not been observed.

The elephants at the San Diego Zoo were maintained for at least 10 years without lice infestation. During the 2 years before lice infestation, elephants were brought to the Zoo from the San Diego Wild

Animal Park where elephant lice had been observed previously. Lice infestation of elephants at the Zoo after the arrival of the new elephants to the herd indicated that the parasites were introduced by previously infested elephants.

Topical treatment of elephant lice infestation at the Park did not completely eradicate the parasite.² However, IM administration of ivermectin¹ to elephants for the treatment of internal parasites at the Park killed the lice on affected elephants.² Local inflammation and soreness at the injection sites warranted discontinuation of using this route of administration. Based on this information, a decision was made to try oral administration of ivermectin in the treatment of elephant lice at the Zoo.

Most members of the order Mallophaga (chewing lice) feed on feathers or hair and only consume blood opportunistically.³ Elephant lice are distinctive in this order because their mouthparts are on

ence on blood resulted in exposure to circulating ivermectin in the treated elephants.

In the elephants of this report, no serious skin lesions were associated with the lice infestation. Dermatitis in elephants due to *Haematomyzus elephantis* has been reported.⁴ Since diagnosis is relatively easy and because the parasites appear to be extremely sensitive to low doses of ivermectin, control of the parasite is accomplished easily.

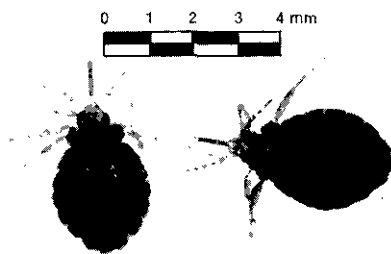


Fig 1—Photomicrograph of 2 elephant lice, *Haematomyzus elephantis*, removed from an elephant at the San Diego Zoo. Notice the elongated anterior projections that support the chewing mouthparts. Each segment of the bar graph represents 1 millimeter.

the end of a thin projection (Fig 1) and because the lice are obligate blood consumers. Their depend-

1. Eqvalan, Merck and Co, Rahway, NJ.
2. Oosterhuis JE, San Diego Wild Animal Park, San Diego, Calif: Personal communication, 1984.

3. Schmidt GD, Roberts LS. *Foundations of parasitology*. 2nd ed. St Louis: CV Mosby Co, 1981;635-637.

4. Raghavan RS, Reddy KR, Khan GA. Dermatitis in elephants caused by the louse *Haematomyzus elephantis*. *Indian Vet J* 1968;45:700-701.

Dr. Karesh's present address is Woodland Park Zoological Gardens, 5500 Phinney Ave North, Seattle, WA 98103.